

Giant Isolated Hydatid Cyst of Spleen

Mehdi Soufi¹, Ghizlane Kharrassa², Khanoussi wafae², Zahi Ismaili², Tijani El haroudi¹, Mohammed Bouziane².

1. Department of digestive Surgery, Faculty of medicine Oujda, University Mohammed first, Oujda -Morocco

2. Department of gastroenterology, Faculty of medicine Oujda, University Mohammed first, Oujda -Morocco

Abstract:

Liver is most commonly involved organ in hydatid cyst. Primary splenic hydatid cysts are rare; we report a case of an isolated giant hydatid cyst of spleen in a 17-year-old man. The diagnosis was confirmed by imaging findings and serology. Partial cystectomy was performed with success. In cystic lesions of spleen, hydatid cyst should be kept in patrician's mind in the differential diagnosis. Although splenectomy is the gold standard for treating hydatid disease of the spleen, in young patient spleen-preserving surgery seems give good results.

Running title: Giant HCS

Keys words: spleen-preserving surgery, splenectomy, hydatid cyst, spleen

Corresponding Author: Mehdi Soufi, MD, Division of digestive and oncological Surgery, Oujda CHU, faculty of medicine. University Mohammed first

Bp 4847 Oujda université 60049, Oujda Morocco

(Tel: +212661212924; Email: drsoufimehdi@hotmail.fr)

Introduction:

Hydatid disease is a helminthic anthroponosis with worldwide distribution that is caused by the larval stage of *Echinococcus granulosus* [1]. Liver and Lungs are the most common sites of involvement in adults. Echinococcal cysts are mostly found in the liver and lungs but the disease can occur almost anywhere in the body [1]. Usually, splenic involvement in hydatid cysts follows systemic dissemination or intra peritoneal spread following ruptured hepatic hydatid cyst. Primary hydatid disease of the spleen is very rare even in endemic areas [2]. We report a case of an isolated giant hydatid cyst of spleen of a 17-year-old man. Treated successfully by a spleen-preserving surgery.

Case Report:

A 17-year-old young man admitted to our department with the complaint of abdominal pain localized in the left upper quadrant for the last 3 months. His physical examination revealed a splenomegaly. Immunoblot assay for *Echinococcus* was positive. His laboratory tests showed normal results of the serum and urine examinations, No eosinophilia was found. Chest X-ray revealed no pathological signs. An abdominal ultrasonography showed a 20 cm multivesicular cystic mass of spleen (figure 1). Contrast enhanced CT scans detected a huge single 20×16×18cm cystic mass located in the spleen. It had well-defined borders and contained multiple, round, daughter cysts in the periphery of the lesion with calcification (Figure 2,3,4). The patient underwent a laparotomy. A large splenic cystic mass was identified, attached to

diaphragm, and tail of the pancreas (figure 5). The abdomen was packed with 10% hypertonic saline soaked pads in order to protect peritoneal soilage. A partial cystectomy without splenectomy was performed. Histologic examination of the specimen resection

FIGURE 2

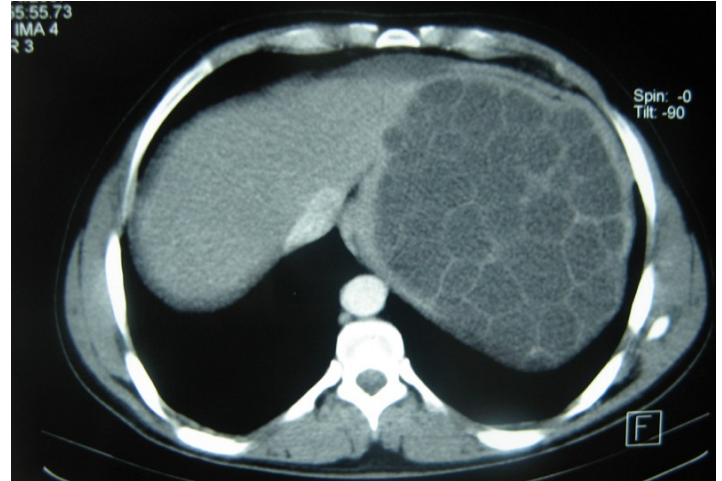


FIGURE 3

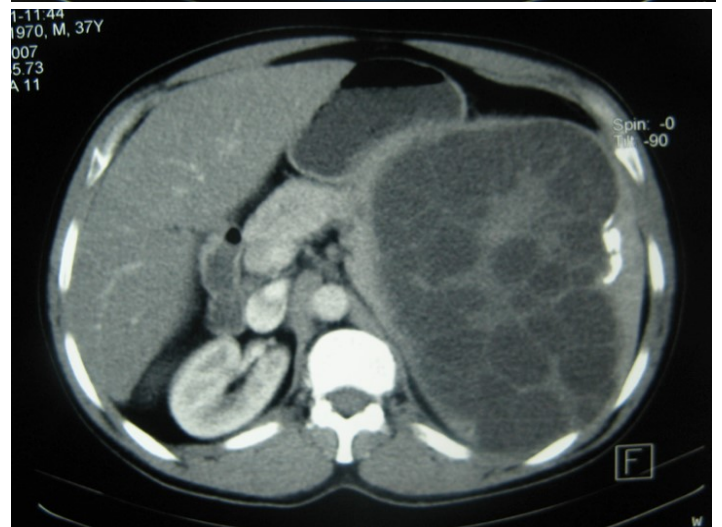

FIGURE 4

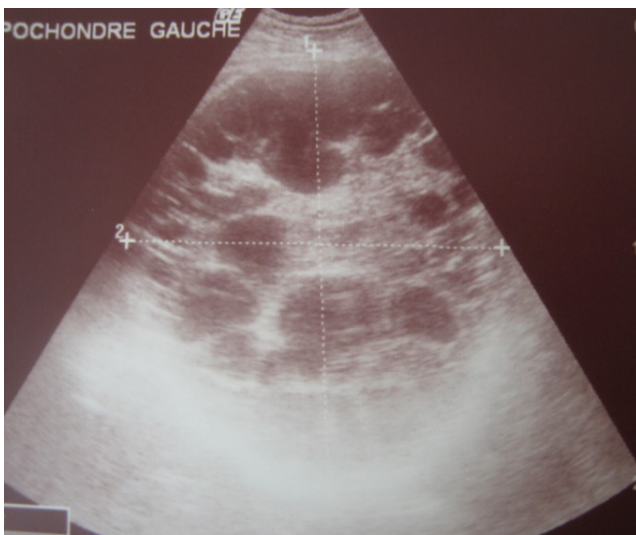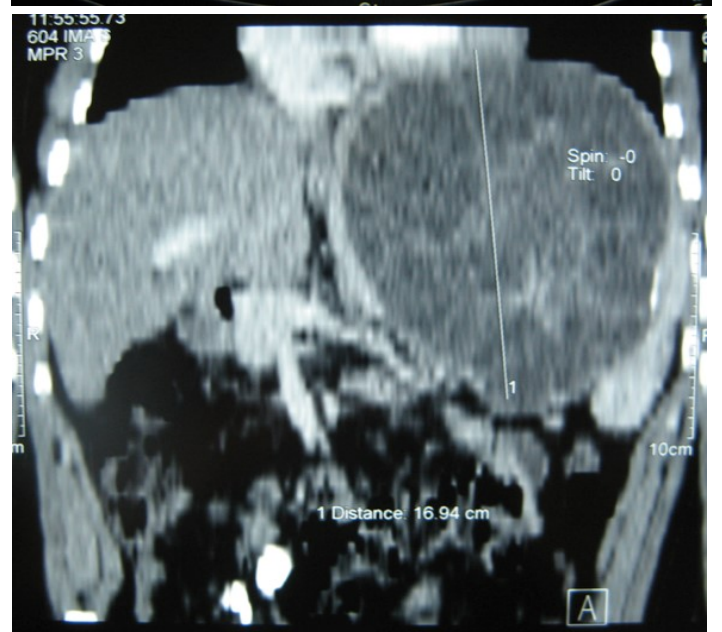


Figure 1: Ultrasonography showing a 20 cm multivesicular cystic mass of spleen

Figure 2,3,4: CT showing a huge single 20×16×18cm cystic mass located in the spleen

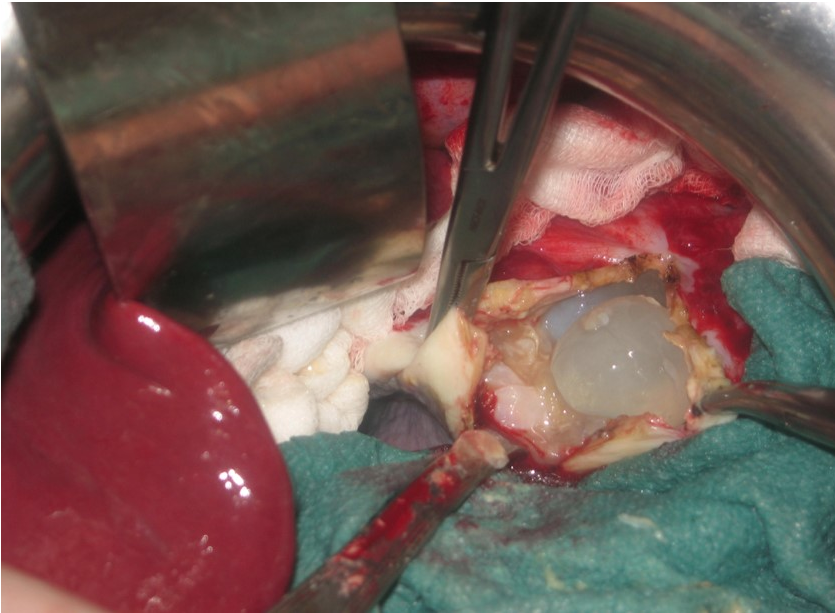


Figure 5: Intraoperative view showing multivesicular spleen hydatid cyst.

showed an echinococcal organism residing within the hydatid cyst. The patient was discharged after 4 postoperative days. 600 mg per a day of Albendazole therapy was instated postoperatively and continued for 6 months. Two years after surgery the patient is well with disease free.

Discussion:

Hydatid disease is a helminthic anthrozoosis caused by the larval stage of *Echinococcus Granulosus* due to the close associations among sheep, dogs, and humans [1]. Humans are the intermediate hosts and contract the infection accidentally. Man acts as the end stage of the larval life cycle. It is a systemic zoonosis particularly widespread among the Middle East countries and the Mediterranean region [1]. The liver is the most frequent location of parasitic cysts but Hydatid disease can occur almost anywhere in the body [2,3]. Primary hydatid cyst of spleen is extremely rare, with an incidence of 2 to 3%, even in the endemic regions [4]. In our case, only isolated splenic disease was found without pulmonary, hepatic, and any other tissue involvement. When the eggs of parasite escape the liver-lung barrier (15%) they can cause a primary infestation wherever in the body through the arterial route [4,5].

Patients with splenic hydatid cyst are usually asymptomatic or had non-specific symptoms [4]. The most common finding is incidentally discovered

splenomegaly [5]. Our patient had a discomfort, pain in the left upper quadrant of the abdomen. Some patients may present with complications such as infection of the cyst, rupture of the cyst into the peritoneal cavity, hypersplenism, and anaphylactic choc fistulization to adjacent organs (colon, stomach and diaphragm) [6,7,8]. In some cases pre-operative diagnosis can be difficult especially if radiological findings are non specific and serologic tests are negative [9]. In our patient combination of imaging modalities and serologic tests confirms the diagnosis of isolated hydatid cyst of spleen. Abdominal X-rays may be able to show crumpled egg shell-like calcifications in the splenic area.

Ultrasonography is helpful in detecting Calcification of the cyst wall, presence of daughter cysts, cystic membranes, septa or hydatid sand [10]. Lesions are usually heterogeneous with indistinct margins, showing alveolar appearance. Multiple small round cysts with solid components are frequent. [10,11].

Ct scan is useful for diagnosis and screening, although there are a variety of pathognomonic signs of hydatid disease on imaging, they are not always present. Other cystic lesions of spleen, such as abscess, hematoma, or pseudocyst may be a diagnostic dilemma [5,12]. CT may show the cystic lesion with or without daughter cysts within the spleen with an attenuation value near that of water without any contrast enhancement [10,11]. Hematological examination may reveal eosinophilia. Immunoelectrophoresis, enzyme-linked immunosorbent assay (ELISA), latex agglutination, and indirect haemagglutination test are helpful for the diagnosis [13]. A negative serology does not rule out cystic echinococcosis. In these cases the diagnosis can be difficult. Although the sensitivity of serological testing is not clearly dependent on the extent of disease, it does appear to be dependent on cyst stage. [14]. echinococcal IgG ELISA test has perhaps the highest positive predictive value among the available serological tests, but unfortunately may only have a negative predictive value of <90% [14]. A rapid immunochromatography test kit using the recombinant Em18 antigen was recently developed. It seems to be simple, reliable, and easy-to-use [15].

The treatment is principally surgical. [5,6,16]. Total splenectomy, partial splenectomy, cyst enucleation and unroofing with omentoplasty are the reported surgical techniques to treat splenic hydatid disease [17]. Laparoscopic approach has also been described for uncomplicated hydatid cyst of the spleen [18]. In our case the cyst was attached to diaphragm, tail of the pancreas and retroperitoneum, we performed a partial cystectomy without any dissection of other organs. In the literature, there is no significant difference in recurrence rates between splenectomy and spleen-sparing surgery [16].

The presence of multiple splenic cysts or communication between the spleen and nearby organs total splenectomy must be preferred [17]. In young patient splenectomy may have a several complication (10%) such as hemorrhage, pancreatic or gastric injuries, thromboembolic phenomena and post splenectomy infection, in these case some surgeons prefer conservative surgery [16].

We think that in huge cyst of spleen especially in young patient total splenectomy including organ involvement may be dangerous for a benign lesion. Albendazole is an effective adjuvant therapy in the treatment of hydatid cyst. it decreases the viability of cysts at the time of surgery and significantly reduces the chances of cyst recurrence [19]. The chemotherapy is indicated in patients who are at high risk for surgery, after spillage during surgery and as a concomitant therapy with percutaneous drainage [19].

Conclusion

Primary hydatid cyst of spleen is rare. It is still difficult to differentiate between parasitic and non-parasitic splenic cysts. Combination of CT scan remains the most sensitive investigations for diagnosis. This case suggests that Hydatid disease should be considered as a differential diagnosis in every patient with a cystic mass of the Spleen. If mortality and morbidity rates are very low, total splenectomy may be the treatment of choice in adults, but in children spleen-preserving surgery should be considered to prevent complications.

Competing Interest: No benefits in any form have been received or will be received from a commercial party related directly or indirectly to the subject of this article.

References:

1. Rinaldi F, Brunetti E, Neumayr A, Maestri M, Goblirsch S, Tamarozzi F. Cystic echinococcosis of the liver: A primer for hepatologists. *World J Hepatol.* 2014 May 27; 6(5):293-305.
2. Rasheed K, Zargar SA, Telwani AA. Hydatid cyst of spleen: a diagnostic challenge. *N Am J Med Sci.* 2013; 5(1): 10–20.
3. Fernández-Ruiz M, Guerra-Vales JM, Enguita-Valls AB, Vila-Santos J, García-Borda FJ, Morales-Gutiérrez C. Splenic hydatid cyst, a rare location of extrahepatic echinococcosis: Report of six cases. *Eur J Intern Med.* 2008;19: 51–e53
4. Wani RA, Malik AA, Chowdri NA, Wani KA, Naqash SH. Primary extrahepatic abdominal hydatidosis. *Int J Surg.* 2005;3:125–7.
5. Malik AA, ul Bari S, Younis M, Wani KA, Rather AA. Primary splenic hydatidosis. *Indian J Gastroenterol.* 2011 ;30(4):175-7.
6. Lewall DB, McCorkell SJ. Rupture of echinococcal cysts: diagnosis, classification, and clinical implications. *AJR Am J Roentgenol.* 1986;146:391–4.
7. Alfigeme I, Martin M, Hernandez J, Huertas C. Rupture of a long-standing splenic hydatid cyst into the bronchial tree. *Clin Infect Dis.* 1994;19:992–4.
8. Teke Z., Yagci A.B., Atalay A.O., Kabay B. Splenic hydatid cyst perforating into the colon manifesting as massive lower gastrointestinal bleeding: an unusual presentation of disseminated abdominal echinococcosis. *Singapore Medical Journal.* 2008;49:113–116.
9. Makkar M, Gupta C, Singh DP, Kaur S, Mahajan N. Giant isolated splenic hydatidosis. *Trop Parasitol.* 2012 ;2(1):74-6
10. Czermak BV, Akhan O, Hiemetzberger R, Zelger B, Vogel W, Jaschke W, Rieger M, Kim SY, Lim JH. Echinococcosis of the liver. *Abdom Imaging.* 2008 ;33(2):133-43
11. Von Sinner WN. Imaging of cystic echinococcosis. *Acta Tropica.* 1997;67(1–2):67-89.

12. Durgun V, Kapan S, Kapan M, Karabiçak I, Aydoğan F, Goksoy E. Primary splenic hydatidosis. *Dig Surg.* 2003;20:38–41.
13. Soufi M, Lahlou MK, Messrouri R, Benamr S, Essadel A, Mdaghri J, Mohammadine E, Taghy A, Settaf A, Chad B. Hydatid cyst of the psoas: a report of two cases]. *J Radiol.* 2010 ;91(12 Pt 1):1292-4.
14. Force L, Torres JM, Carrillo A, Buscà J. Evaluation of eight serological tests in the diagnosis of human echinococcosis and follow-up. *Clin Infect Dis.* 1992; 15:473-80.
15. Knapp J, Sako Y, Grenouillet F, Bresson-Hadni S, Richou C, Gbaguidi-Haore H, Ito A & Millon L: Comparison of the serological tests ICT and ELISA for the diagnosis of alveolar echinococcosis in France. *Parasite*, 2014, 21 34.
16. Akbulut S, Sogutcu N, Eris C. Hydatid disease of the spleen: single-center experience and a brief literature review. *J Gastrointest Surg.* 2013 ;17 (10):1784-95.
17. Atmatzidis K, Papaziogas B, Mirelis C, Pavlidis T, Papaziogas T. Splenectomy versus spleen-preserving surgery for splenic echinococcosis. *Dig Surg.* 2003;20(6):527-31.
18. Polat FR. Hydatid cyst: Open or laparoscopic approach? A retrospective analysis. *Surg Laparosc Endosc Percutan Tech* 2012; 22:264-6
19. Shams-UI-Bari, Arif SH, Malik AA, Khaja AR, Dass TA, Naikoo ZA. Role of albendazole in the management of hydatid cyst liver. *Saudi J Gastroenterol.* 2011 ;17(5):343-7.